



Head & Neck Tumor Board

Tamer Ghanem M.D. Ph.D.

Director Head & Neck Fellowship

Otolaryngology Head & Neck Surgery Department

Henry Ford Hospital



Disclosures

Olympus Corporation Consultant



Case 1

- 49 y.o. F with an incidental right hard palate lesion noted by her dental hygienist
- Work up and biopsy revealed an adenoid cystic carcinoma invading right maxillary sinus and pterygopalatine fossa

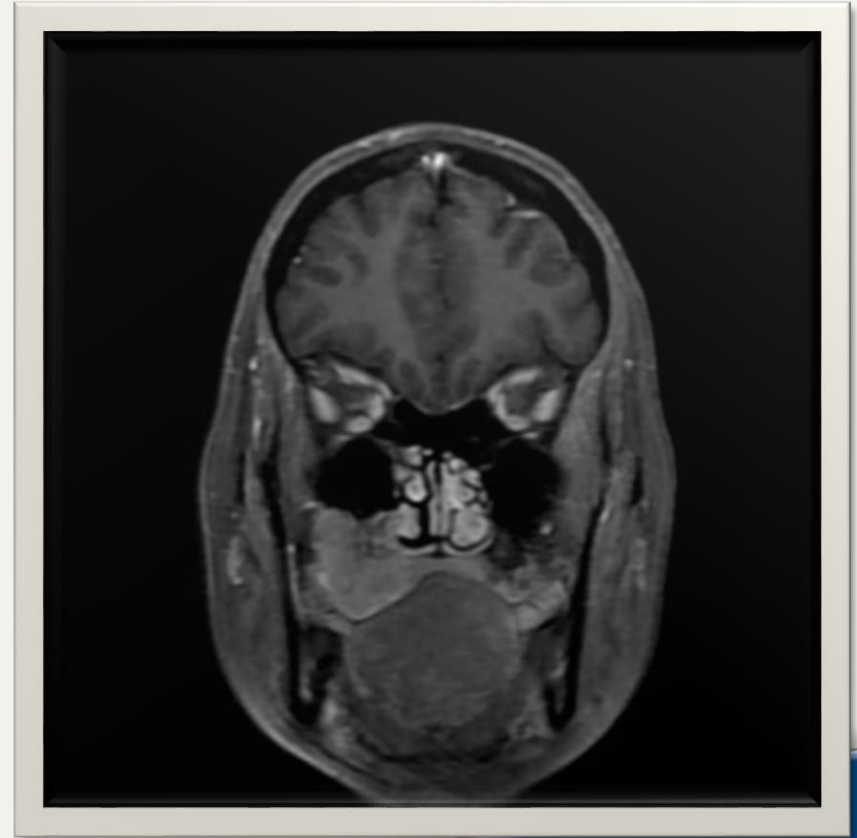
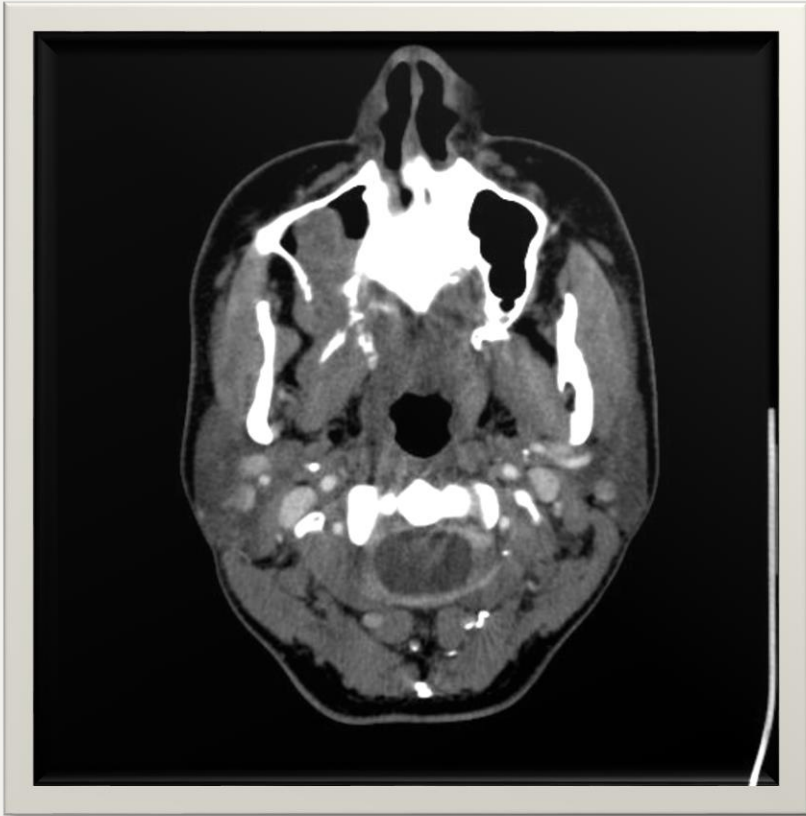

Case 1

- Work up
 - Imaging?
 - Consults?



Case 1

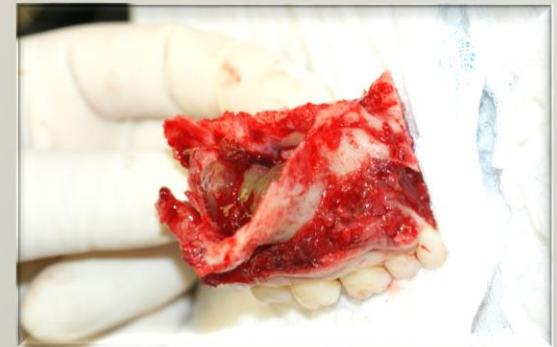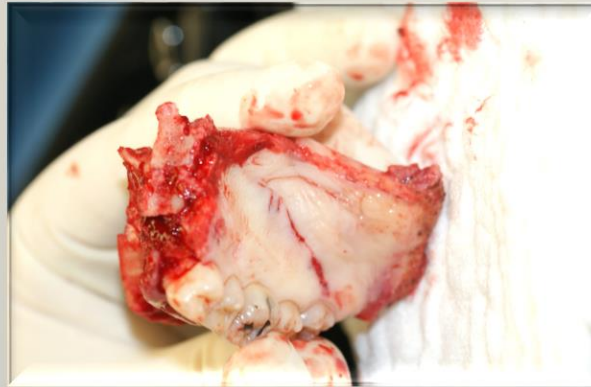
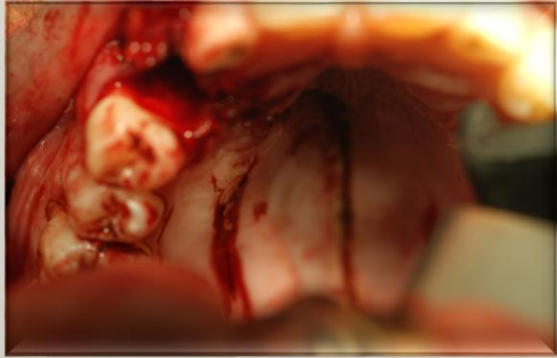


Case 1

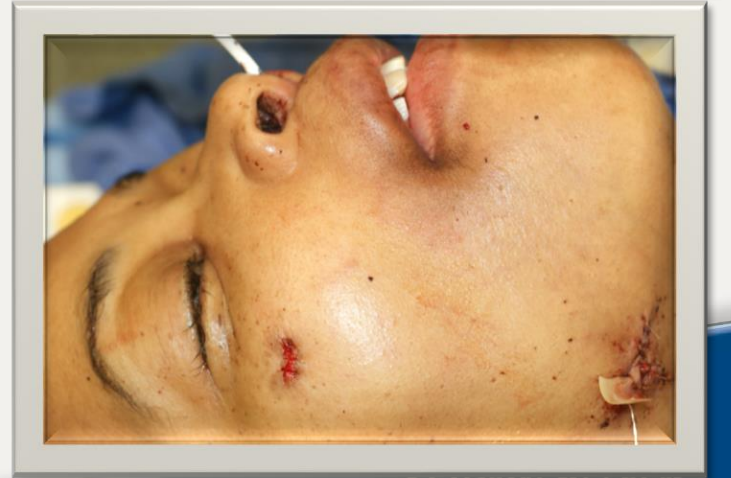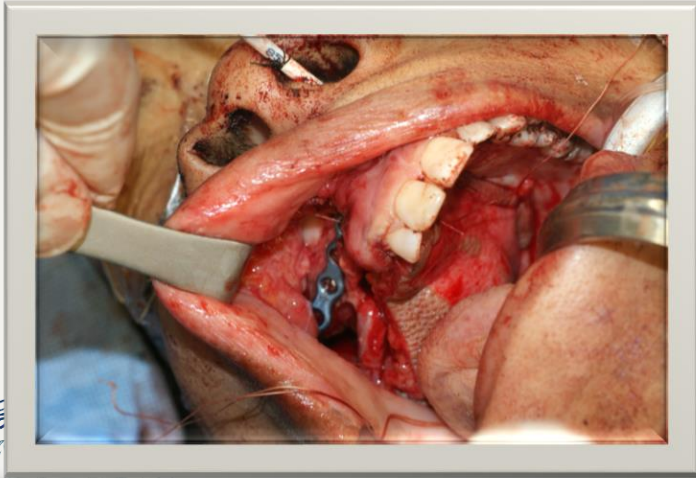
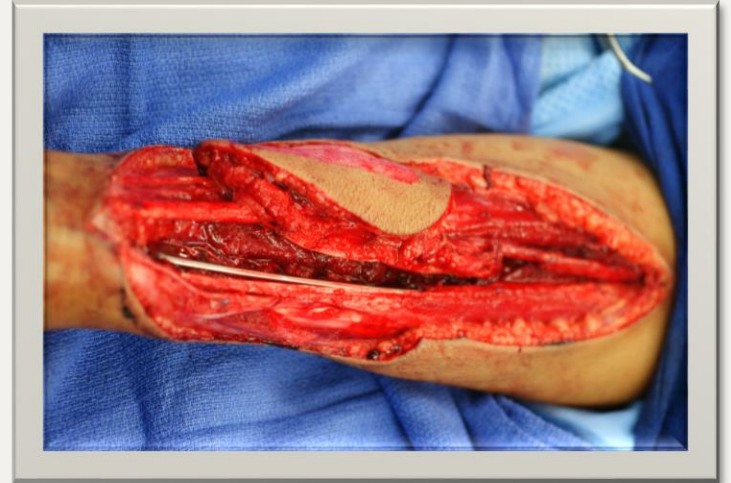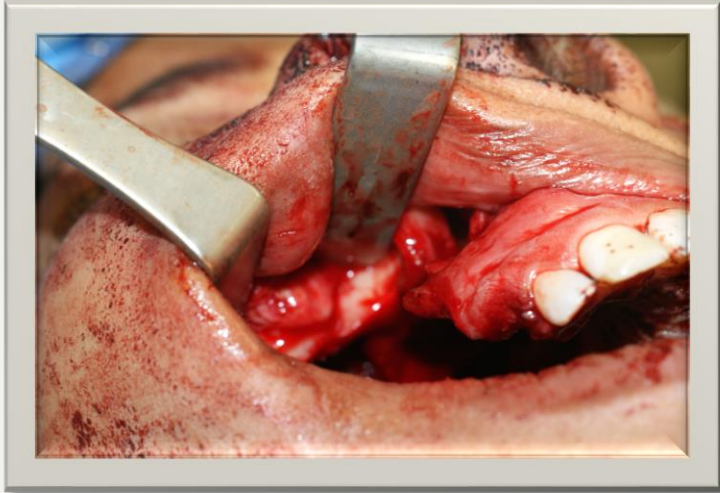
- Management
 - Surgery?
 - XRT ?
 - Chemo?



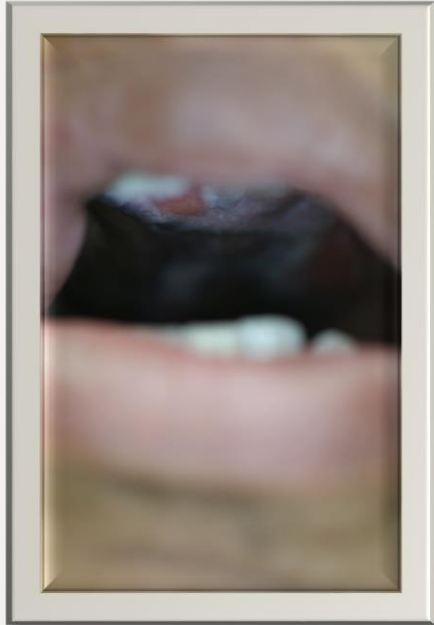

Case 1



Case 1



Case 1



4 weeks post op

3 months post op

Case 1

- Follow-up
 - How frequently?
 - How long?
 - Imaging?

