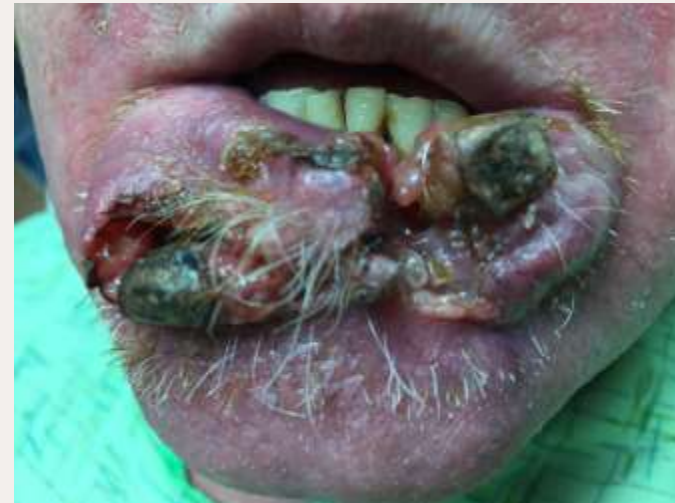
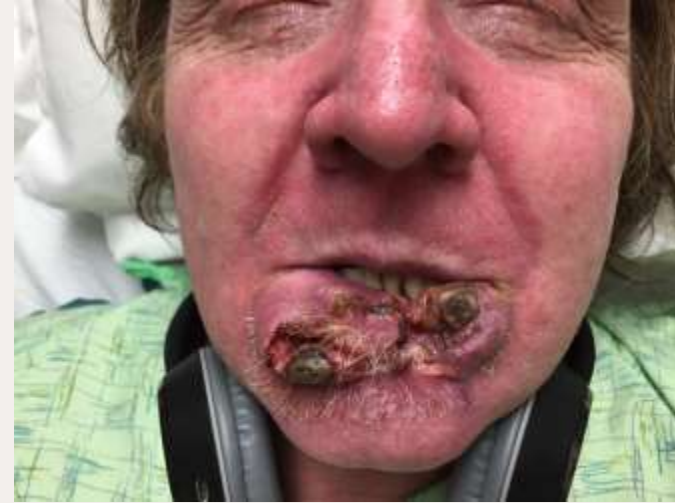
Case 2

- 55 y.o. M transferred from another hospital due to bleeding from lip
- Had the lesion for over one year and growing



Case 2

- Patient admits to drinking a fifth of hard liquor per day
- Due to pain he has not been eating and drinking as much



Case 2

- Work up?
 - Imaging?
 - What to do about alcohol history?
 - What to do about mal-nutrition?

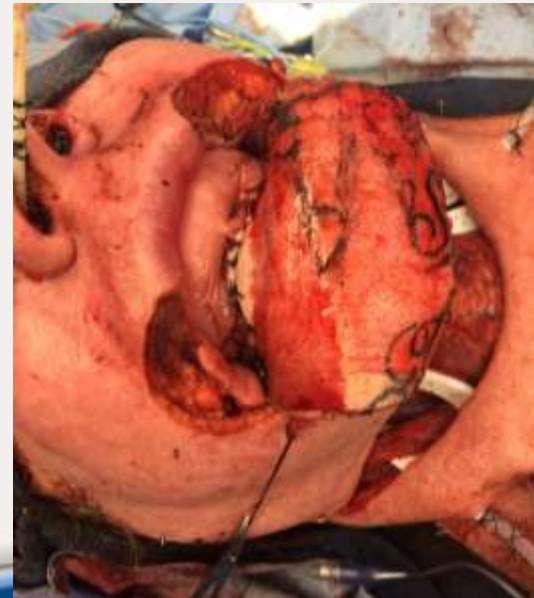
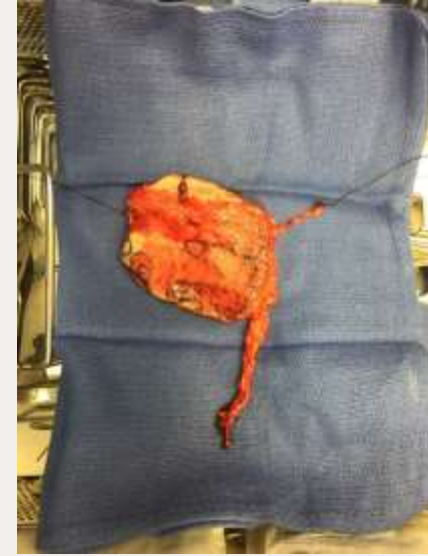
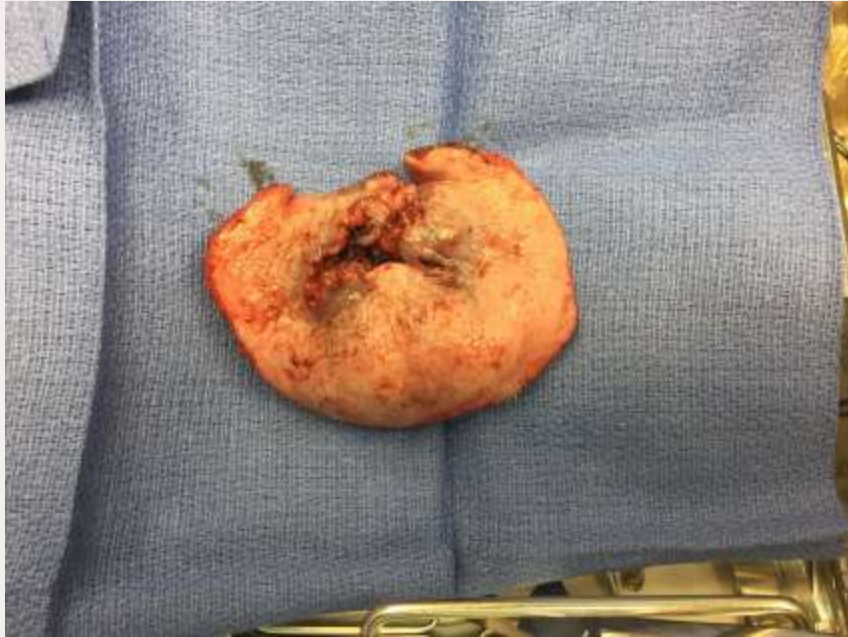
Case 2

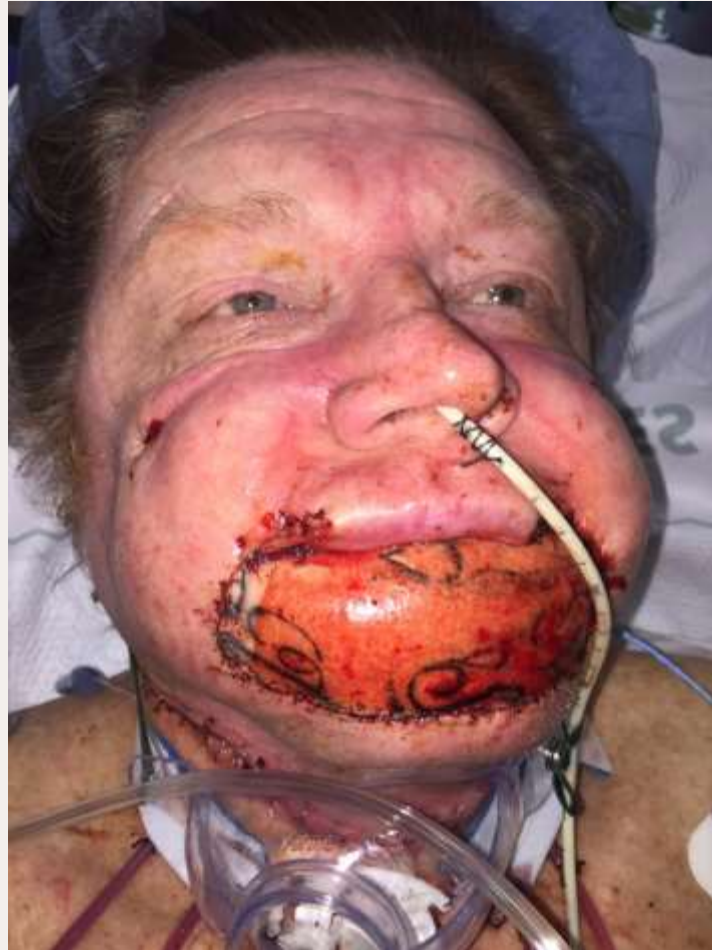- Management
 - Surgery?
 - Radiation?
 - Chemo?



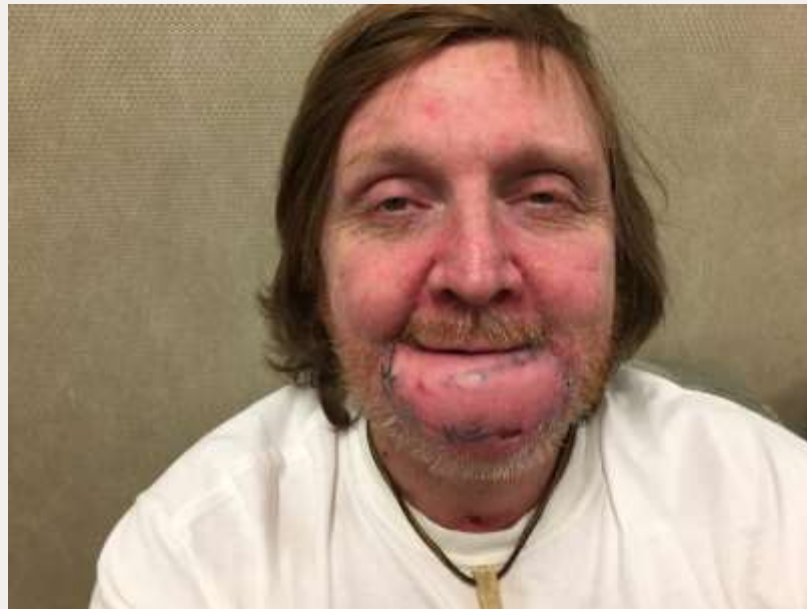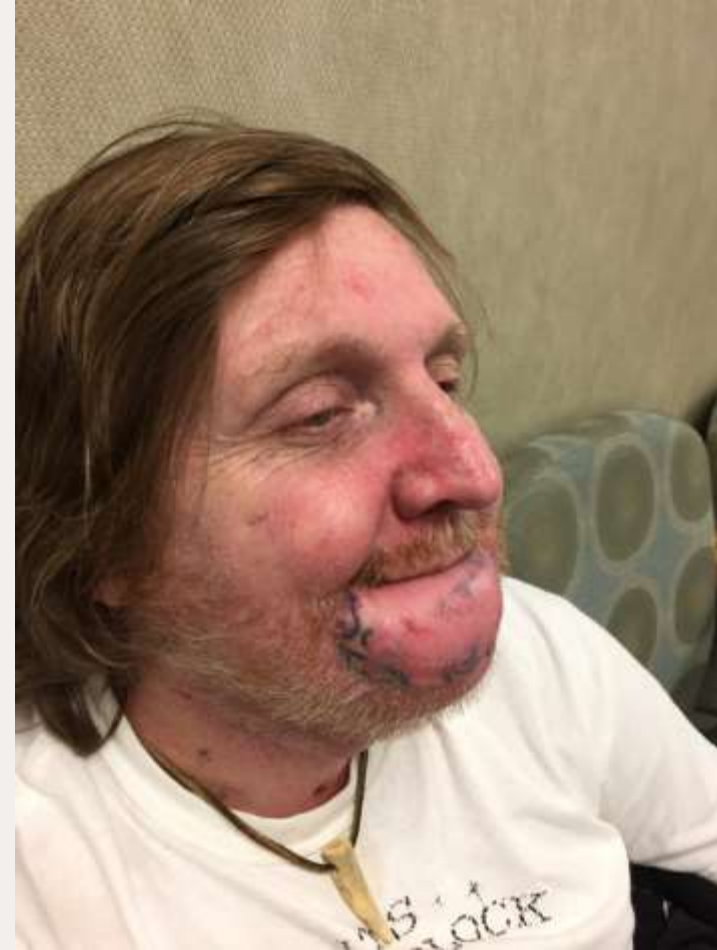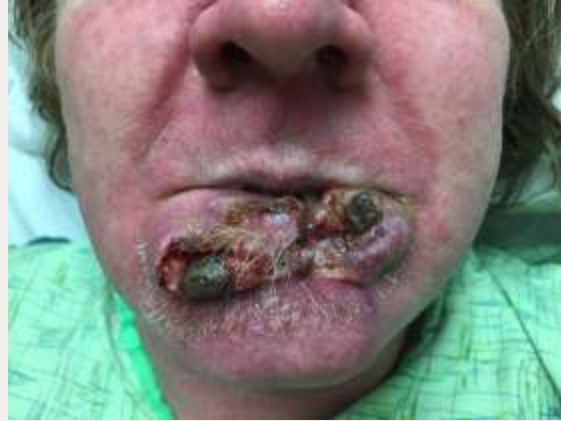Case 2



Case 2



Case 2



3 Weesks

Case 3

- 56 y.o. M with a 3 month history of left sided neck mass
- Denies sore throat, otalgia, dysphagia, change of voice
- Exam firm, non-mobile 4 cm neck mass. No other masses
- Scope exam clear



Case 3



Case 4

- (Salvage oropharyngeal case)

